



SECTION Cardiovascular Disorders

SUBJECT Arterial Hypertension

Renovascular Hypertension

Renovascular hypertension is BP elevation due to partial or complete occlusion of one or more renal arteries or their branches. It is usually asymptomatic unless long-standing. A bruit can be heard over one or both renal arteries in < 50% of patients. Diagnosis is by physical examination and renal imaging with duplex ultrasonography, radionuclide imaging, or magnetic resonance angiography. Angiography is done before definitive treatment with surgery or angioplasty.

Renovascular disease is one of the most common causes of curable hypertension but accounts for < 2% of all cases of hypertension. Stenosis or occlusion of one or both main renal arteries, an accessory renal artery, or any of their branches can cause hypertension by stimulating release of renin from juxtaglomerular cells of the affected kidney. The area of the arterial lumen must be decreased by $\geq 70\%$ before stenosis is likely to cause hypertension. For unknown reasons, renovascular hypertension is much less common among blacks than among whites.

Overall, about $\frac{2}{3}$ of cases are caused by atherosclerosis and $\frac{1}{3}$ by fibromuscular dysplasia. Atherosclerosis is more common among men > 50 and affects mainly the proximal $\frac{1}{3}$ of the renal artery. Fibromuscular dysplasia is more common among younger patients (usually women) and usually affects the distal $\frac{2}{3}$ of the main renal artery and the branches of the renal arteries. Rarer causes include emboli, trauma, inadvertent ligation during surgery, and extrinsic compression of the renal pedicle by tumors.

Renovascular hypertension is characterized by high cardiac output and high peripheral resistance.

Symptoms and Signs

Renovascular hypertension is usually asymptomatic. A systolic-diastolic bruit in the epigastrium, usually transmitted to one or both upper quadrants and sometimes to the back, is almost pathognomonic, but it is present in only about 50% of patients with fibromuscular dysplasia and is rare in patients with renal atherosclerosis.

Renovascular hypertension should be suspected if diastolic hypertension develops abruptly in a patient < 30 or > 50; if new or previously stable hypertension rapidly worsens within 6 mo; or if hypertension is initially very severe, associated with worsening renal function, or highly refractory to drug treatment. A history of trauma to the back or flank or acute pain in this region with or without hematuria suggests renovascular hypertension (possibly due to arterial injury), but these historical findings are rare. Asymmetric renal size (discovered incidentally during imaging tests) and recurrent episodes of unexplained acute pulmonary edema or heart failure also suggest it.

Diagnosis

- Initial identification with ultrasonography, magnetic resonance angiography, or radionuclide

imaging

- Confirmation with renal angiography (also may be therapeutic)

If renovascular hypertension is suspected, ultrasonography, magnetic resonance angiography (MRA), or radionuclide imaging may be done to identify patients who should have renal angiography, the definitive test.

Duplex Doppler ultrasonography can assess renal blood flow and is a reliable noninvasive method for identifying significant stenosis (eg, > 60%) in the main renal arteries. Sensitivity and specificity approach 90% with experienced technicians. It is less accurate with branch stenosis.

MRA is a more accurate and specific noninvasive test to assess the renal arteries.

Radionuclide imaging is often done before and after an oral dose of captopril 50 mg. The ACE inhibitor causes the affected artery to narrow, producing decreased perfusion on the scintiscan.

Narrowing also causes an increase in serum renin, which is measured before and after captopril. This test may be less reliable in blacks and in patients with decreased renal function.

Renal angiography is done if MRA indicates a lesion amenable to angioplasty or stenting or if other screening tests are positive.

Digital subtraction angiography with selective injection of the renal arteries can also confirm the diagnosis, but angioplasty or stent placement cannot be done in the same procedure.

Measurements of renal vein renin activity are sometimes misleading and, unless surgery is being considered, are not necessary.

However, in unilateral disease, a renal vein renin activity ratio of > 1.5 (affected to unaffected side) usually predicts a good outcome with revascularization. The test is done when patients are depleted of Na, stimulating the release of renin.

Treatment

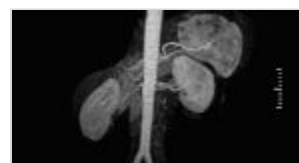- Angioplasty sometimes with stent placement
- Rarely, bypass graft

Opening the obstructed renal artery using angioplasty with or without a stent usually relieves hypertension if the renal vein renin activity ratio is > 1.5:1. Even when the ratio is lower, revascularization or removal of the affected kidney often cures hypertension.

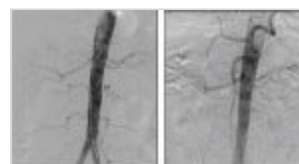
Percutaneous transluminal angioplasty (PTA) is recommended for most patients, including younger patients with fibromuscular dysplasia of the renal artery. Placement of a stent reduces the risk of restenosis; antiplatelet drugs (aspirin, clopidogrel) are given afterward. Saphenous vein bypass grafting is recommended only when extensive disease in the renal artery branches makes PTA technically unfeasible. Sometimes complete surgical revascularization requires microvascular techniques that can only be done ex vivo with autotransplantation of the kidney. Cure rate is 90% in appropriately selected patients; surgical mortality rate is < 1%. Medical treatment is always preferable to nephrectomy in young patients whose kidneys cannot be revascularized for technical reasons.

Atherosclerotic lesions respond less well to surgery and angioplasty than do lesions due to

Renovascular Hypertension (Magnetic Resonance Angiography)



Renovascular Hypertension (Digital Subtraction Angiography)



fibromuscular dysplasia, presumably because patients are older and vascular disease is more extensive. Hypertension may persist, and surgical complications are more common. Surgical mortality rate is higher than that in young patients with fibromuscular dysplasia. Restenosis occurs within 2 yr after PTA in up to 50% of patients with renovascular atherosclerosis, especially when the lesion is located at the ostium of the renal artery, and, with stenting, in about 25%.

Without treatment, the prognosis is similar to that for patients with untreated primary hypertension. Medical treatment is inadequate without intervention to alleviate the stenosis, but aggressive medical treatment in adherent patients usually ameliorates and sometimes controls hypertension.

Last full review/revision July 2007 by George L. Bakris, MD

[CONTACT US](#) [SITE MAP](#)  [PRIVACY POLICY](#) [TERMS OF USE](#) [COPYRIGHT 1995-2007 MERCK & CO., INC.](#)